

# Musculoskeletal and neurological complications following coronary artery bypass graft surgery: A comparison between saphenous vein and internal mammary artery grafting

Doa El-Ansary<sup>1</sup>, Roger Adams<sup>2</sup> and Ajay Ghandi<sup>3</sup>

<sup>1</sup>The Canberra Hospital <sup>2</sup>The University of Sydney <sup>3</sup>Tweed Heads District Hospital

The internal (thoracic) mammary artery (IMA) is currently the vessel of choice for coronary artery bypass grafting (CABG), due to its long term patency. The purpose of this study was to compare the incidence and nature of musculoskeletal and neurological complications following saphenous vein grafting (SVG) and internal mammary artery grafting (IMAG). Ninety-seven patients were screened by a physiotherapist for musculoskeletal and neurological complications three to six weeks following cardiac surgery. The incidence of new musculoskeletal and neurological complications was significantly higher in patients following IMAG (78.5 per cent) than SVG (45 per cent) ( $p < 0.001$ ,  $\chi^2_{(1)} = 17.04$ ). A significant association between musculoskeletal complications affecting the anterior chest and harvesting of the IMA was also demonstrated. [El-Ansary D, Adams R and Ghandi A (2000): Musculoskeletal and neurological complications following coronary artery bypass graft surgery: A comparison between saphenous vein and internal mammary artery grafting. *Australian Journal of Physiotherapy* 46: 19-25]

Key words: Brachial Plexus; Coronary Artery Bypass; Chest Pain, Heart Surgery, Postoperative Complications

## Introduction

---

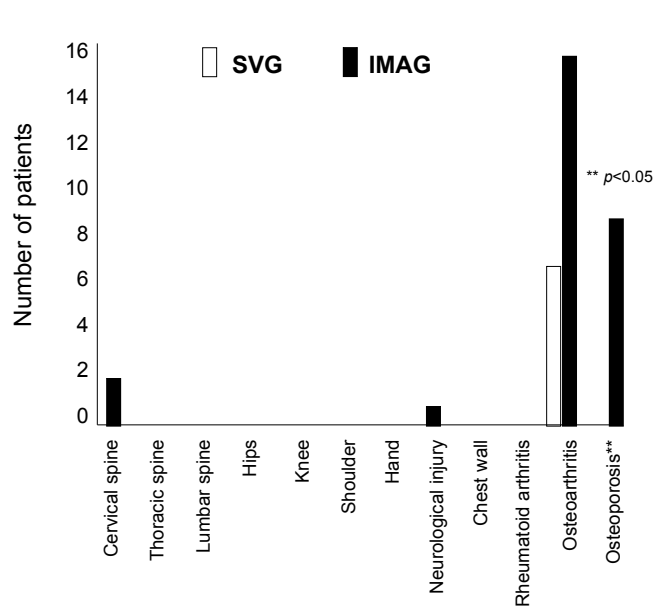
The internal (thoracic) mammary artery (IMA) is currently the vessel of choice for coronary artery bypass grafting (CABG) (Kouchoukos et al 1990), as its patency is superior to that of venous conduits (Sabiston and Spencer 1990). Despite this benefit, several drawbacks of IMA grafting have been described, including sternal wound complications and comparatively greater post-operative blood loss (Kouchoukos et al 1990).

Although musculoskeletal and neurological complications following CABG have been observed clinically, most of these are accepted as being unavoidable consequences of surgery. Stiller et al (1997) reported that approximately 30 per cent of patients developed musculoskeletal complications that interfered with their level of comfort and function 8-10 weeks following cardiac surgery. Further, an association between IMA harvest and musculoskeletal complaints was demonstrated by Roy et al (1988). In that study, 39 per cent of patients with IMAG had musculoskeletal complaints and/or

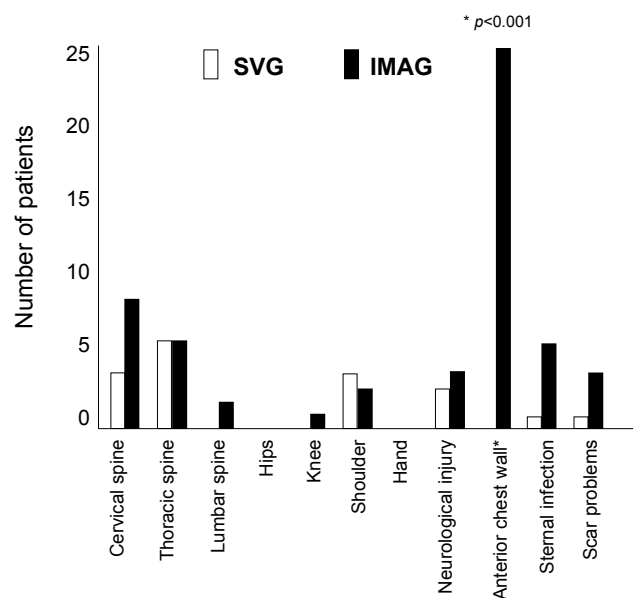
neurological dysfunction, compared with 17 per cent of patients with SVG (Roy et al 1988). Upper limb neurological complications after CABG have been documented in seven prospective studies with the incidence ranging from 1.9 per cent to 18.3 per cent and the brachial plexus was involved in 80 per cent of cases (Hanson et al 1983, Keates et al 1975, Roy et al 1988, Shaw et al 1985, Sotaniemi 1980, Vander Salm et al 1980, Vander Salm et al 1982).

It is postulated here that musculoskeletal and neurological dysfunction after CABG may be due to the mechanical demands placed upon the patient during the surgical procedure (El-Ansary 1995, Selvaratnam et al 1994). These demands include sternal retraction, dissection of the IMA, internal jugular cannulisation, patient position and devascularisation of the sternum (El-Ansary 1995, Tomlinson et al 1987, Vander Salm et al 1980, Vander Salm et al 1982).

Over the last five years at The Canberra Hospital, we have observed the occurrence of musculoskeletal and neurological complications in patients who have had



**Figure 1.** Pre-operative musculoskeletal profile for the two groups.



**Figure 2.** Post-operative musculoskeletal profile for the two groups.

cardiac surgery, in particular following IMA harvest. Patients usually presented with these complications three to six weeks following surgery, on admission to the cardiac rehabilitation program (CRP). In addition, several patients presented to the Accident and Emergency Department with chest wall pain following cardiac surgery up to two years previously. Investigation of this chest wall pain revealed it to be musculoskeletal in origin.

We therefore undertook a prospective analysis of consecutive patients who underwent CABG surgery in other states<sup>(a)</sup> and were referred to the CRP, to determine the frequency and nature of musculoskeletal and neurological complications in two patient groups, following IMAG and SVG. It was felt that this was important in order to identify the physiotherapy service needs of this patient population.

## Method

All patients having CABG (via a median sternotomy) attending the CRP following surgery interstate (New South Wales or Victoria) over a 10-month period were eligible for inclusion in the study. Those who gave their written and informed consent were included in the study (n = 110). Patients who were not referred to

the CRP or those for whom details of the graft(s) received were unavailable were excluded from the study (n = 13).

According to the nature of the graft(s), patients were allocated to one of the following groups: SVG alone (n = 33), or one/two IMA graft/s alone or combined with vein grafts (n = 64).

A cardiac nurse and a physiotherapist conducted a subjective examination on each patient prior to entry into the CRP three to six weeks post-cardiac surgery. Data collected included a record of cardiac risk factors, neurological and/or musculoskeletal problems prior to and following cardiac surgery as well as prior physiotherapy intervention. Cardiac risk factors were included to gain insight into the cardiac and general health profile of each group and to observe whether the two groups were comparable.

Subjects identified by the subjective examination as having specific musculoskeletal and neurological complaints underwent an objective examination by a single experienced manipulative physiotherapist prior to the commencement of the CRP. The assessment procedure consisted of a routine subjective and objective musculoskeletal and neurological physical examination (Kaltenborn et al 1994, Maitland 1983).

**Table 1** - Descriptive data of the two operative groups

	SVG (n = 33)	IMAG (n = 65)
Mean age (years)	62.5	58
No. of males	28	57
No. of females	5	8
Past CABG (yes)	4	4
Pre-existing lung condition	5	3
Obesity	14	19
Smoker	23	36
Diabetes	4	8
Hypertension	23 **	23
Past myocardial infarction	20	30

Note - unless otherwise indicated, all values represent number of patients

\*\*  $p < 0.01$

In addition, specific motion testing of the ribs (passive accessory and passive physiological) (Kaltenborn et al 1994) and a rating scale for quantifying sternal instability was also used (El-Ansary et al 2000). Inter-therapist and intra-therapist reliability for the sternal instability scale were 0.97 and 0.98 respectively (El-Ansary and Elkins 1997). Neurological function of the peripheral nerves of the upper limb was also tested where muscle wasting, loss of function/weakness or altered sensation were present (Kaltenborn et al 1994) and positive findings were noted to be consistent with neurological injury. Tenderness on palpation, restriction of passive, passive accessory, passive physiological and/or active motion by pain and/or stiffness were used to assign a primary and, if required, secondary diagnosis to each patient. The anatomical location of the musculoskeletal and neurological structures involved was recorded for each patient.

Post-operative sternal infection was considered to be present in patients in whom sternal instability developed in association with a positive wound culture and a surgical procedure (removal of sternal wires, debridement and secondary closure) was necessary (Kouchoukos et al 1990).

**Analysis** Analyses were completed using the Excel statistical software package on a Powerbook

computer. Data were analysed using the chi-square test with probability values of less than 0.05 deemed significant.

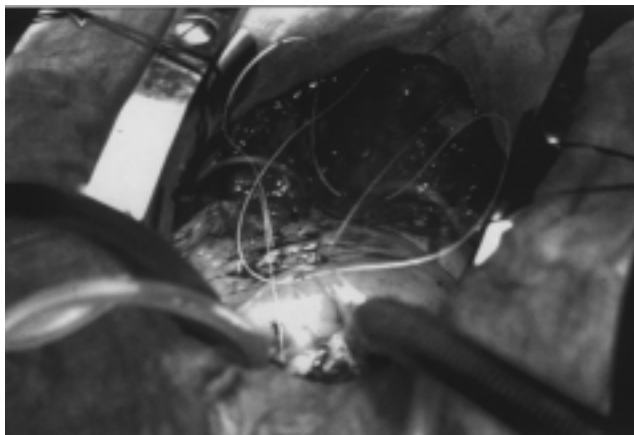
## Results

**Pre-operative data** The sample consisted of 97 patients. Table 1 displays descriptive data for the two groups. The groups were homogenous for age and sex. As expected, the number of patients in the IMA group (n = 65) exceeded those in the SVG group (n = 33) as IMA grafts are more frequently used. The general health profile of the two groups was comparable in terms of cardiac risk factors (Table 1), with the exception of hypertension, which was significantly higher in the SVG group ( $p < 0.01$ ,  $\chi^2_{(1)} = 10.35$ ).

The incidence of pre-operative musculoskeletal and neurological complications is illustrated in Figure 1. A significantly higher proportion of patients who had the IMA procedure also had osteoporosis ( $p < 0.05$ ,  $\chi^2_{(1)} = 5.04$ ).

**Post-operative data** The incidence and location of musculoskeletal and neurological complications three to six weeks post-operatively is presented in Figure 2. The types of symptoms described by patients included pain, stiffness, weakness, numbness, instability, and altered sensation (tingling, pins and needles). Demonstrated neurological signs accompanied neurological symptoms on physical examination.

The incidence of cervical, thoracic and lumbar spine, hip, knee, shoulder and hand complications were all comparable between the two groups. However, the incidence of post-operative chest wall problems affecting the anterior thoracic cage (ie sternocostal, costochondral, interchondral, manubriosternal, xiphisternal joints and associated musculature) was significantly higher ( $p < 0.001$ ,  $\chi^2_{(1)} = 17.04$ ) in the IMAG group (25/65 patients; 38.5 per cent) than in the SVG group (0/33 patients; 0 per cent). Physical findings included localised pain and tenderness on palpation of the muscles and joints of the anterior thoracic cage; restriction of passive, passive accessory, passive physiological and/or active motion by pain, instability and/or stiffness. These complications affected the patient's level of comfort and function and, in turn, their capacity to return to



**Figure 3.** Retraction of the chest wall during coronary artery bypass grafting.

work or engage in leisure activities. It is proposed that these complications may be due to subluxation or strain of the manubriosternal, sternocostal and costochondral joints; fractured ribs; fractured or subluxed cartilages; as well as acute injury to the anterior chest wall musculature.

A total of 10 patients (10.3 per cent) presented with neurological complications. All of these injuries were of the brachial plexus: two patients (6 per cent) in the SVG group and seven patients (10.7 per cent) in the IMAG group had a lesion affecting the lower trunk (C8-T1) on the left side and one patient (3 per cent) from the SVG group had a left sided suprascapular nerve palsy. There was no significant difference between the two groups with respect to the incidence of post-operative neurological complications.

The proportion of patients who developed sternal infection and associated sternal instability in the IMAG group (6/65 patients; 9.2 per cent) was not significantly different from those in the SVG group (1/33 patients; 3 per cent).

Scar problems, including hyperalgesia, paraesthesia, inflammation and hypertrophic scarring were noted but analysis showed that these were not significantly different between the two groups.


The association between the development of new musculoskeletal and neurological complications and the use of IMA grafting was also investigated. The proportion of patients who had IMAG surgery and

developed new musculoskeletal and/or neurological complications (51/65 patients; 78.5 per cent) was found to be significantly higher than those who developed new complaints following SVG surgery (15/33 patients; 45 per cent,  $p < 0.001$ ).

## Discussion

The development of musculoskeletal and neurological complications following CABG surgery via a median sternotomy incision may be explained by factors that are particular to this surgical procedure. These include use of a sternal retractor, patient position during surgery, cannulation of the internal jugular veins and the relative devascularisation of the sternum once its main blood supply has been harvested.

During both SVG and IMAG surgery, a retractor is placed on the sternum and opened to the desired



**Figure 4.** Retraction and elevation of the chest wall by a 'Ruletract' during harvest of the internal mammary artery.

extent to allow adequate exposure of the heart and surrounding vasculature (Figure 3). In addition, during an IMAG procedure, a specifically designed retractor (eg Rultract, Favalaro) retracts and everts the upper ribs asymmetrically at an angle varying from 20 degrees to 70 degrees from the horizontal plane until the IMA is harvested (Figure 4). Retraction and eversion of the upper ribs is a non-physiological movement (Moore 1992). This fact alone may account for the significantly higher incidence of anterior chest wall injury in the IMAG group (25/65 patients; 38.5 per cent).

Vander Salm et al (1980) have demonstrated that median sternotomy can cause first rib fractures and that these may be associated with injury of the inferior trunk (C8-T1) of the brachial plexus. In addition, Treasure et al (1980) proposed that local pressure on the nerves by the first rib may result in ischaemia of the lower trunk of the brachial plexus.

The 10.3 per cent incidence of upper limb neurological complications in this study is similar to previously reported findings (Hanson et al 1983, Roy et al 1988, Vander Salm et al 1980). When upper limb neurological complications alone were compared, there were no differences attributable to IMAG surgery.

Several patient positions for CABG are documented in the literature. However, since none of the positions are peculiar to the IMAG procedure, patient position can offer little explanation for the difference in the incidence of anterior chest wall complications.

Although placement of an internal jugular cannula has been implicated as a cause of brachial plexus injury after cardiac surgery (Hanson et al 1983, Lederman 1982), several studies have disputed this as a potential cause of neurological complications (Roy et al 1988, Tomlinson et al 1987, Vander Salm et al 1982). It is therefore unlikely that cannulation may contribute to neurological complications of the upper limb and cervical spine.

Although some of the literature seems to suggest a higher incidence of sternal wound complications (eg sternal infection and associated sternal instability) following grafting of both IMAs, presumably as a result of devascularisation of the sternum (El-Ansary and Elkins 1997, Kouchoukous et al 1990, Loop et al

1990) due to interruption of its main blood supply (Moore 1992), this was not confirmed by this study.

The overall incidence of musculoskeletal and neurological problems in this study was higher than previously reported by Roy et al (1988) and Stiller et al (1997). The sample in this study was representative of several surgical methods, as patients underwent surgery at more than seven different centres in New South Wales or Victoria and were therefore exposed to a wide variety of surgical procedures (technique and equipment) and post-operative care. The variation in results may be due to different assessment techniques used as well as the fact that patients in this study were evaluated earlier in the post-operative period (three to six weeks) compared with eight to 10 weeks in the study by Stiller et al (1997). In addition, this is the first study to include complications of the anterior chest wall, as it was argued that the surgical procedure primarily affects this region and that chest wall pain of musculoskeletal origin was a significant problem for both the patient and hospital staff. Stiller et al (1997) and Roy et al (1988) gave consideration to injuries of the back and shoulder and upper extremity and nerves respectively. Exclusion of anterior chest wall complications from the current data analysis yields an overall incidence of musculoskeletal and neurological complications similar to that reported by Stiller et al (1997) and Roy et al (1988). This incidence is 45 per cent for the SVG group and 43 per cent for the IMAG group, with no significant difference between the two groups - the same result as that reported by Stiller et al (1997). However, inclusion of anterior chest wall complications demonstrated a significant association between complaints in this region and harvesting of the IMA.

The existence of musculoskeletal and neurological complications following CABG surgery has prompted several physiotherapy service initiatives at The Canberra Hospital. These include the introduction of an outpatient physiotherapy clinic to service the specific needs of cardiothoracic surgical patients, pre-operative liaison with anaesthetists and cardiothoracic surgeons with respect to pre-existing problems and the use of specific stretches to target mobility and enhance circulation of the thoracic cage. Communication regarding the nature of musculoskeletal and neurological complications following CABG surgery, and avenues for improved management of these problems, was also initiated with cardiologists and cardiothoracic surgeons, as

well as general practitioners and physiotherapists in the community.

Many physiotherapists spend considerable time improving ventilation and facilitating clearance of secretions in the post-operative period. Stiller et al (1995) and Stiller et al (1997) have reported a low incidence (7.5 per cent and 7.4 per cent) of clinically significant post-operative chest complications in patients not receiving prophylactic chest physiotherapy after coronary artery surgery. These findings have prompted a review of post-operative chest physiotherapy protocols. Given the high incidence of musculoskeletal and neurological complications, we recommend assessment and treatment of these problems in the acute post-operative period, and continuation following discharge from hospital if warranted. Screening and evaluation of these complications may also take place whilst the patient is attending the CRP. Liaison with the multidisciplinary staff involved in the CRP, the cardiothoracic surgeon, cardiologist and general practitioner is important in order to ensure co-ordinated management of these problems.

Stiller et al (1997) reported that routine active range of motion (ROM) exercises of the upper limb and trunk commencing in the early post-operative period have no significant effect on the incidence of musculoskeletal problems eight to 10 weeks post-operatively. It is our clinical impression however, that gentle (bilateral) active exercises of the upper limb and trunk may be necessary in the initial post-operative period (up to six weeks) to facilitate a return of pre-operative ROM and reduce generalised discomfort of the anterior chest. In addition, once the sternum is deemed stable (approximately six to eight weeks) the introduction of specific stretches addressing the muscles of the thoracic cage (eg intercostals, pectoralis minor, iliocostalis thoracis) as well as automobilisation of the thoracic spine and ribs (Evjenth and Hamberg 1989) may reduce the incidence of complications and the need for further physiotherapy intervention. However, this requires confirmation through further research.

In addition, given the increasing use of radial artery grafts for CABG, the implications of this on the incidence of scar problems and peripheral nerve complications needs to be evaluated in future.

In conclusion, there has been a change of practice in CABG surgical technique toward IMAG because of its longer patency. A significant association was found between musculoskeletal complications affecting the anterior chest wall and harvesting of the IMA (38.5 per cent,  $p < 0.001$ ). As the IMA becomes more widely used, particularly bilaterally, musculoskeletal and neurological complications are likely to become an ongoing concern. A corresponding change may be needed with respect to physiotherapy practice in the assessment and management of these complications.

**Acknowledgements** We would like to acknowledge Dr Howard Peak (cardiologist and Executive Co-ordinator of Cardiac Rehabilitation), Lorelle Toms (CNC Cardiac Rehabilitation), Dr Peter Bissaker (Director of Cardiac Surgery) and the cardiologists, Pauline Brown (former Director of Physiotherapy) and June Gunning (Director of Physiotherapy) at The Canberra Hospital; Associate Professor Olaf Evjenth and senior academic associate Bill Atkinson (Australian Association of Orthopaedic Manipulative Therapy), for their ongoing support and guidance.

Thanks to Dr Kathy Stiller (senior physiotherapist at the Royal Adelaide Hospital), Dr Tim McKenzie (cardiothoracic surgeon), Dr John Tharion (thoracic surgeon), Mark Elkins and Elizabeth Trickett (senior physiotherapists) at The Canberra Hospital for their assistance in reviewing earlier drafts of this paper. We also extend our appreciation to Lena Culnane and Linda Wells for their administrative assistance, as well as the patients who participated in the study.

Part of the material in this article was presented at the 4th National Cardiothoracic Special Group Conference of the Australian Physiotherapy Association in Melbourne, 1995.

**Footnote** <sup>(a)</sup>This study took place prior to the commencement of cardiac surgery at The Canberra Hospital in February 1998.

## References

- 
- El-Ansary D (1995): Musculoskeletal problems following CABG: a comparison between saphenous vein and internal mammary grafting. (Abstract) Proceedings of the 4th National Cardiothoracic Special Group Conference of the Australian Physiotherapy Association. Melbourne, p. 29.

- El-Ansary D and Elkins M (1997): Sternal instability following coronary artery bypass grafting. (Abstract) Proceedings of the 5th National Cardiothoracic Special Group Conference of the Australian Physiotherapy Association. Perth, p. 39.
- El-Ansary D, Adams R, Toms L and Elkins M (2000): Sternal instability following coronary artery bypass grafting. *Physiotherapy Theory and Practice*. In Press.
- Evjenth O and Hamberg J (1989): Autostretching - the Complete Manual of Specific Stretching. Stockholm: Alfa Rehab Forlag.
- Hanson MR, Breuer AC, Furlan AJ, Lederman RJ, Wilbourn AJ, Cosgrove DM, Loop FD and Estafanous FG (1983): Mechanism and frequency of brachial plexus injury in open-heart surgery: a prospective analysis. *Annals of Thoracic Surgery* 36: 675-679.
- Kaltenborn F, Evjenth O, Kaltenborn TB and Vollowitz E (1994): The Spine - Basic Evaluation and Mobilisation Techniques. (2nd ed.) Oslo: Olaf Norlis Bokhandel.
- Keates JRW, Innocenti DM and Ross DN (1975): Mononeuritis multiplex- a complication of open-heart surgery. *Journal of Thoracic and Cardiovascular Surgery* 69: 816-819.
- Kouchoukos NT, Wareing TH, Murphy SF, Pelate C and Marshall WG (1990): Risks of bilateral internal mammary artery bypass grafting. *Annals of Thoracic Surgery* 49: 210-219.
- Lederman RJ, Breuer AC, Hanson MR, Furlan AJ, Loop FD, Cosgrove DM, Estafanous FG and Greenstreet RL (1982): Peripheral nervous system complications of coronary artery bypass graft surgery. *Annals of Neurology* 12: 297-301.
- Loop FD, Lytle BW, Cosgrove DM, Mahfood S, McHenry MC, Goormastic M, Stewart RW, Golding LAR and Taylor PC (1990): Sternal wound complications after isolated coronary artery bypass grafting: early and late mortality, morbidity and cost of care. *Annals of Thoracic Surgery* 49: 179-187.
- Maitland GD (1983): Vertebral Manipulation (4th ed.) London: Butterworths.
- Moore KL (1992): Clinically Oriented Anatomy (3rd ed.) Baltimore: Williams and Wilkins.
- Roy RC, Stafford MA and Charlton JE (1988): Nerve injury and musculoskeletal complaints after cardiac surgery: influence of IMA dissection and left arm position. *Anesthesia and Analgesia* 67: 277-279.
- Sabiston D and Spencer FC (1990): Surgery of the Chest (Vol. 2) (5th ed.) London: WB Saunders Company.
- Selvaratnam PJ, Matyas TA and Glasgow EF (1994): Noninvasive discrimination of brachial plexus involvement in upper limb pain. *Spine* 19: 26-33.
- Shaw PJ, Bates D, Cartlidge NEF, Heaviside D, Julian DG, and Shaw DA (1985): Early neurological complications of coronary artery bypass surgery. *British Medical Journal* 291: 1384-1387.
- Sotaniemi KA (1988): Brain damage and neurological outcome after open-heart surgery. *Journal of Neurology, Neurosurgery and Psychiatry* 43: 127-135.
- Stillier K, Crawford R, McInnes M, Montarello J and Hall B (1995): The incidence of pulmonary complications in patients not receiving prophylactic chest physiotherapy after cardiac surgery. *Physiotherapy Theory and Practice* 11: 205-208.
- Stillier K, McInnes M, Huff N and Hall B (1997): Do exercises prevent musculoskeletal complications after cardiac surgery? *Physiotherapy Theory and Practice* 13: 117-126.
- Tomlinson DL, Hirsch IA, Kodali SV and Slogoff S (1987): Protecting the brachial plexus during median sternotomy. *Journal of Thoracic and Cardiovascular Surgery* 94: 297-301.
- Treasure T, Garnett R, O'Connor J and Treasure JL (1980): Injury of the lower trunk of the brachial plexus as a complication of median sternotomy for cardiac surgery. *Annals of the Royal College of Surgeons* 62: 378.
- Vander Salm TJ, Cerada JM and Cutler BS (1980): Brachial plexus injury following median sternotomy (Part I). *Journal of Thoracic and Cardiovascular Surgery* 80: 447-452.
- Vander Salm TJ, Cutler BS and Okike ON (1982): Brachial plexus injury following median sternotomy (Part 2). *Journal of Thoracic and Cardiovascular Surgery* 83: 914-917.